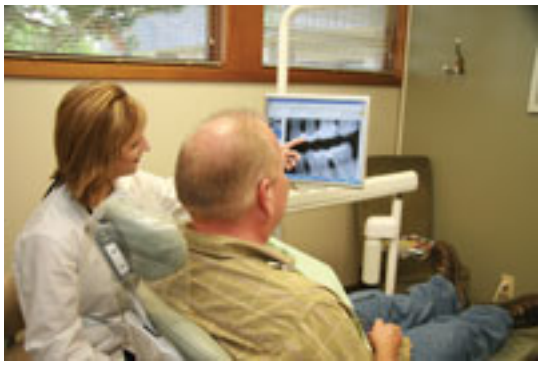

Figure 1. Explaining the radiograph showing decay on tooth No. 13.

Figure 2. An intraoral photo was taken to share with our patient. The existing amalgam fil

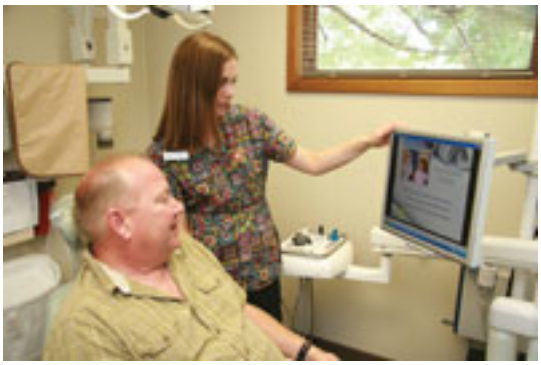

Figure 3. The patient views the CAESY presentation (CAESY Systems) with our treatmen

Figure 4. The area was powdered prior to the initial image acquisition.

Figure 5. The CEREC camera (Sirona) was used to capture a digital impression for creat

Figure 6. The completed preparation with retraction cord placed.

Figure 7. The crown was digitally designed with the CEREC system (Sirona).

Figure 8. The crown was milled in the CEREC MC XL (Sirona).

Figure 9. Occlusal view of the completed restoration.

Figure 10. Buccal view of the completed restoration.

Tom M. Limoli, Jr

This includes photographic images, including those obtained by intra- and extraoral cameras, exclu

This code is not to identify the photographic duplication of radiographs.

This procedure is frequently overlooked, yet it is a necessary key to third-party reimbursement. T

Diagnostic photography should be used to provide and confirm that what x-rays fail to show. Ser

Ever since the caveman began drawing on walls, it has been widely acknowledged that, “A pictu

When diagnostic photographs are submitted, the attached narrative need simply state: “The encl

Table. Oral/Facial Photographic Images

Code	Description	Lower	Low	Medium	High	Higher	National Average	National RV
D0350	Oral/facial photographic images							$24

CDT-2009/2010. Copyright American Dental Association. All rights reserved. Fee Data. Copyright Limoli and Associates/Atlanta Dental Consultants. This data represents 100% of the 90th percentile. The relative value is based upon the national average and not the individual columns of broad-based data. The abbreviated code numbers and descriptors are not intended to be a comprehensive listing. Customized fee schedule analysis for your individual office is available for a charge from Limoli and Associates/Atlanta Dental Consultants at **(800) 344-2633** or visit Web site limoli.com
.

Postoperative Education and Instructions

At that time, I gave the patient a brief explanation of what to expect during the next stage, and the assistant then had the patient view an additional CAESY presentation, "Post-Op Instructions: Permanent Crowns." This presentation is a quick overview of the typical instructions given to patients following placement of a crown. It advises them to avoid chewing anything until after the anesthesia wears off, to not chew ice or hard objects, and to brush and floss normally to care for the crown. The presentation also advises patients on what to do if they experience discomfort after the procedure, suggesting use of a desensitizing toothpaste for a few days if teeth are sensitive to heat, cold, or pressure following the procedure. Patients are also warned to take any antibiotics or medication only as prescribed, and instructed to rinse with warm salt water to reduce discomfort or swelling. The presentation explains that it is normal for gums to be sore for several days after the procedure. Finally, it emphasizes that patients should not hesitate to call the office if their bite feels uneven, if discomfort lasts beyond a few days, or if they have any questions.

After the patient completed viewing the presentation, he was again given an opportunity for questions. The patient was ultimately very pleased with the process and with the aesthetic look and comfortable feel of his new crown (Figures 9 and 10).

CLOSING COMMENTS

A procedure such as this one can be lengthy, and does necessitate several breaks during which the dentist has to leave the patient to fabricate and glaze the crown. Without a well-organized education program, patients in these cases can potentially become anxious after being left alone or might feel neglected because of the delay. However, making thorough use of CAESY presentations, our team is able to fully explain these procedures in advance, both helping patients prepare and giving them a better understanding of what the dental team is accomplishing. Furthermore, the thoroughness of the postoperatory instructions is very helpful, as these presentations cover a variety of issues that may come up once the patient reaches home. Knowing that each patient has been consistently briefed on some of the most common "What if?" questions is a significant help in minimizing postprocedure anxieties and calls to the office.

With every patient, our team aims to use the technology in the office to its fullest to educate and help patients take ownership of their situation. We have recently adopted a system in which I perform new patient examinations with the assistance of my treatment coordinators in my treatment rooms. This gives me an opportunity to welcome patients to the office right away, let them know what we're about, show them images of their teeth taken with the intraoral camera, and then use CAESY patient education to better illustrate their individual condition.

With these technological tools, we often hear feedback such as, “Wow, I didn’t know about that,” and, “I’ve never seen that before.” Impressing patients with these capabilities helps keep our word-of-mouth referrals coming and also helps us retain patients as we track their success with new images. I believe that every time a patient visits the office, we have an opportunity to educate. Utilizing tools such as the intraoral camera and CAESY system helps us accomplish our patient education goals consistently and effectively. These technologies help increase patient knowledge and acceptance of proposed treatment, and improve the chance for greater satisfaction once delivered.

Dr. Lewis received her dental degree from Southern Illinois University School of Dental Medicine in 2004 and practices in Decatur, Ill. She is active in the state and local dental societies, currently serving as president of the Decatur District Dental Society. She can be reached at (217) 877-1742 or via e-mail at dral@amandalewisdmd.com .

Disclosure: Dr. Lewis reports no conflicts of interest.