Written by Clifford J. Ruddle, DDS, FACD, FICD
Tuesday, 30 April 2002 19:00

The purpose of this series of articles is to provide useful information that will enable dentists to predictably shape root canals for three-dimensional obturation. The information in these articles is intended to help clinicians better understand how to safely use nickel-titanium (NiTi) rotary files. The author's articles previously published in Dentistry Today described the concepts that form the foundation for successfully preparing root canal systems.1-4 Recently, a new generation of files for shaping root canals called the ProTaper system (DENTSPLY Tulsa Dental) has become available. ProTaper's unique geometries and directions for use have been described (Figures 1 and 2).
3-6
This article will focus on the various considerations that will influence predictability and success when finishing the apical one third. Where appropriate, the technique principles specific to the ProTaper system will be described; however, many of the principles discussed are applicable to all NiTi rotary systems.

FINISHING THE APICAL ONE THIRD



Figure 1. *The ProTaper NiTi rotary set of files.* ***Figure 2.*** *This is comprised of just three files.* *The canals of thi*



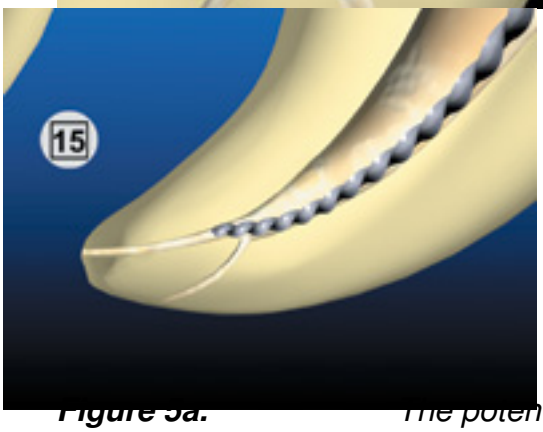

Figure 5a: *The potential problem of immediately trying to negotiate a tight, large c*

Figure 5b: *A tighter, more c*

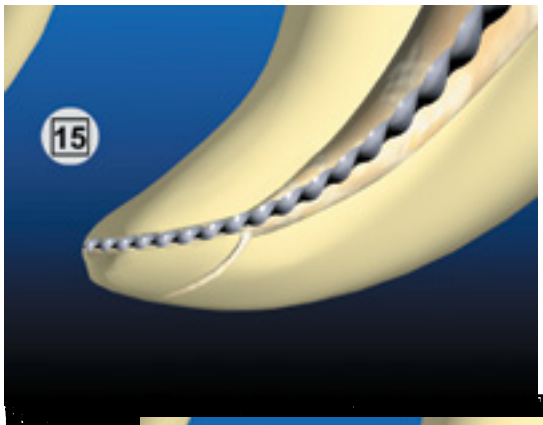

[redacted]*oducible*



[redacted]*fae is st*

[redacted]*ar were ga*

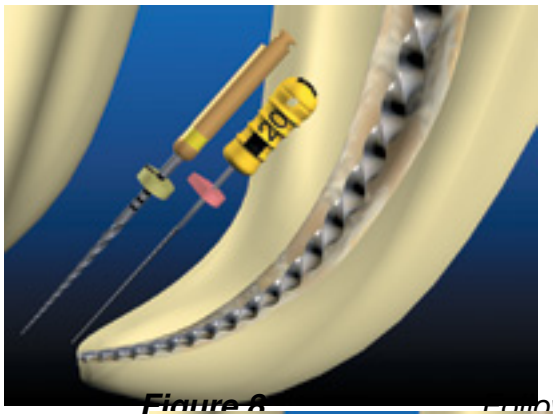

Figure 8. *Following the use of the 20/0.07 F1 rotary file to length, the foramen is*





[redacted] *the use*

Figure 9. This radiograph illustrates that a

Figure 10. This radiograph illustrates that a gutta-percha point demonstrates

strates tha



Each inst

five treate

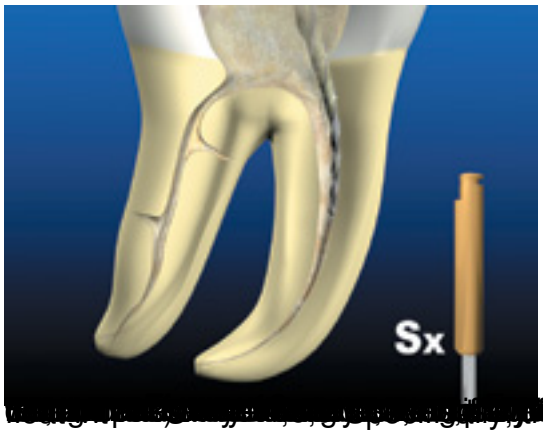
Sx