Endodontic performance is enhanced when clinicians thoughtfully view different horizontally angulated, preoperative radiographic images, visualize minimally invasive, yet complete, treatment, then use this mental picture to guide each procedural step.[1] There is an old expression…"Start with the end in mind." Before initiating the access preparation, think, visualize, and plan to more effectively execute a predictably successful result.

PRETREATMENT

Prior to endodontic treatment, an interdisciplinary evaluation of pulpally involved teeth should be performed to ensure that optimal health is both possible and attainable. At times, it is advantageous to band and build up a tooth to facilitate subsequent endodontic procedures. Seriously broken-down teeth should be evaluated for periodontal crown lengthening procedures.[2] Crown lengthening facilitates endodontic isolation and enables the restorative dentist to create the ferrule effect and achieve a healthy biological width. [3] When indicated, crown lengthening serves to improve all phases of interdisciplinary treatment. [4]

Pretreatment procedures elevate the potential for endodontic success by improving the predictability of each ensuing step.

Another endodontic pretreatment consideration is whether to access through or remove an existing prosthetic restoration. Clinicians typically access the pulp chamber through a restoration if it is judged to be well fitting, functionally designed, and aesthetically pleasing. If the restoration fails to meet these criteria, then it is typically sacrificed. However, for a variety of reasons, it may be desirable to remove an existing restoration and preserve it intact. The safe and successful dislodgment of any given restoration requires knowledge in all aspects of prosthetic reconstructive dentistry and the selection and use of a few removal devices. [5] Importantly, the clinician must consult with the patient and clearly communicate the risk versus benefit before commencing with disassembly and removal procedures.

ISOLATION

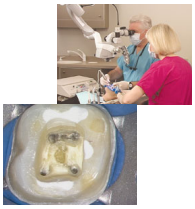

Figure 1a. The microscope (Carl Zeiss) provides magnification, coaxial lighting, and the op

Figure 1b. A photo demonstrates isolation and straight-line access to the orifices. Note the

Excellent vision in conjunction with complete isolation promotes predictably safe and successful endodontic treatment (Figures 1a and 1b). Isolation accomplishes soft-tissue retraction, protects the oral pharynx, and prevents salivary leakage. Fortunately, the vast majority of all teeth can be easily and quickly isolated for endodontic treatment in a one-step procedure. To accomplish this, an appropriately sized hole is punched at a predetermined position through a rubber dam. The rubber dam may be stretched onto a nonmetallic, polymer frame, and then a pre-selected clamp is mounted onto the rubber dam. A nonmetallic frame allows working films to be taken without concern for inadvertent metal superimposition over the region to be viewed. The rubber dam forceps guide the jaws of the clamp over the crown and are released so they securely engage the tooth and do not impinge on soft tissue. An explorer may be used to lift the rubber dam off the facial and lingual wings of the clamp.

Dental floss may be used to work the rubber dam between the contact points and carry it gingivally to establish a dry working field. On occasion, even when the dam has been well-placed, there may be a nuisance contamination leak. As such, caulking materials such as OraSeal (Ultradent Products) are available to secure a fluid-tight treatment environment. Infrequently but on occasion, it may be useful to initiate an endodontic access cavity without a rubber dam to improve orientation. This may be considered when the clinician encounters heavily restored teeth, significant calcification within the pulp chamber, or when the clinical crown is not aligned with the underlying root.

ACCESS OBJECTIVES

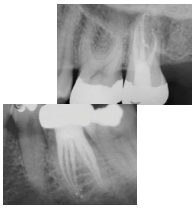

Figure 2a. This post-treatment film demonstrates straight-line access, apical curvature and

Figure 2b. This post-treatment film illustrates straight-line access and that 5 canals were id

Figure 3. This photo demonstrates straight-line access, smoothly prepared and divergent

The access preparation is an essential element for successful endodontics.6 Preparing the endodontic access cavity is a critical step in a series of procedures that potentially leads to the 3-dimensional obturation of the root canal system (Figures 2a and 2b). Access cavities should be cut so the pulpal roof, including all overlying dentin, is removed. The size of the access cavity is primarily influenced by the anatomical position of the orifice(s). The axial walls are extended laterally such that the orifice(s) is just within this outline form. When required, access preparations are further expanded to eliminate any other restrictive interference that could compromise any aspect of ensuing treatment.[7]

Endodontic access cavities should parallel the principles of restorative dentistry. Dentists performing prosthetic dentistry readily appreciate the importance of being able to withdraw a wax pattern from a stone or copper dye without distorting the wax. Endodontically, access objectives are confirmed when all the orifices of a furcated tooth can be visualized without moving the mouth mirror. Cleaning and shaping potentials are dramatically improved when instruments conveniently pass through the occlusal opening, effortlessly slide down smooth axial walls, and are easily inserted into a preflared orifice (Figure 3). Spacious access cavities are an opening for canal preparation. [8-10]

ACCESS TECHNIQUES



Figure 4a. A round bur diamond in conjunction with a water coolant is utilized to initiate ac

Figure 4b. This transmetal bur has a saw-tooth blade configuration that may be used to eff

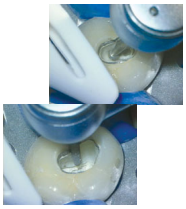

Figure 4c. A surgical length carbide round bur provides a line of sight for safely and progre

Figure 4d. A surgical length tapered diamond provides continuous vision and may be utiliz

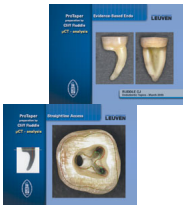

Figure 5a. A µCT image of a mandibular molar demonstrates the distal root has been rem

Figure 5b. The green outline pattern seen in this µCT image demonstrates the original ana

Figure 5c. This µCT image shows before (green) and after (red) shaping procedures. The

Figure 6. A cross-section through the mesial root illustrates that the orifices are generally

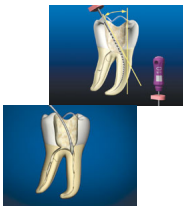

Figure 7a. The handle of a small-sized hand file is frequently “off” axis in furcated teeth du

Figure 7b. The shaft of a GG is arced so the bud will cut and intentionally move the corona

Having knowledge regarding the external and internal anatomy of human teeth is fundamental and serves to prepare the clinician to treat endodontically involved teeth more successfully.[11] From experience, it is best to initially prepare the size of the access window to about 80% of what the final outline form will ultimately expand and become. Initially preparing a close to optimal opening improves vision as the preparation moves deeper into the tooth. Once the pulpal roof has been removed, then the position of the orifice(s) may be identified on the pulpal floor. With anatomical orientation, the position of the axial walls may be adjusted and the access preparation fully expanded and finished accordingly.
[12]

Depending on the material comprising the clinical crown, the appropriate bur is selected to initiate treatment (Figure 4a). At times, subsequent restorative materials require a different bur to improve efficiency while reducing unwanted vibration (Fig-ure 4b). Like a painter painting a canvas, the clinician moves the handpiece utilizing a light, brushing motion. The bur is swept mesial to distal and facial to lingual as the access preparation is extended toward the pulp chamber. A light brushing motion with a new, sharp bur reduces friction and related heat, and affords more control when progressively carrying the ac-cess preparation pulpally. From a patient’s perspective, brush-cutting versus drilling dentin promotes peaceful endodontics, especially when accessing pulpitic teeth. The access cavity is continued until the pulpal roof is penetrated. Upon entry, an appropriately sized, surgical length carbide round bur is placed inside the chamber and is repetitively dragged occlusally until the entire pulpal roof has been removed (Figure 4c).

After completely deroofing the pulp chamber and identifying the orifice(s), a surgical length tapered diamond (Brasseler) may be used to flare, flatten, and finish the axial walls (Figure 4d). The axial walls are tapered so they diverge from the pulpal floor toward the occlusal surface. Smooth, flat, and tapered axial walls improve the refraction of light, and hence, vision. Tapered diamonds serve to create straight-line access to each orifice. When radicular space is available, an explorer may be placed into an orifice to determine the entry angle of any given canal relative to the long axis of the tooth. When radicular space is more restrictive, a small-sized hand file can generally be inserted into the coronal-most aspect of a canal to judge the entry

angle of the canal relative to the long axis of the tooth. Placing a small-sized hand file will disclose the existence of any irregularities or interferences that could pose a nuisance during subsequent cleaning and shaping procedures.

In the author's opinion, Gates Glidden (GG) burs, sizes 1 to 4 (DENTSPLY Maillefer) are the rotary cutting burs of choice to preflare the orifice(s), intentionally relocate the coronal aspect of a canal away from external root concavities, and remove internal triangles of dentin. This procedure establishes a reproducible opening to any canal, facilitating subsequent instrumentation. Research has shown that a single-X Gates, comprising GG sizes 1 to 4 (DENTSPLY Maillefer), or a few GGs can be safely used with a "brushing action" and at a "low speed" of about 750 rpm to selectively cut dentin and produce a final preparation that is centered within the circumferential dimensions of the root (Figures 5a to 5c). The size of the GG initially selected depends on the size of the orifice. As a guideline, select the largest GG that can passively fit into any given orifice, and then proceed from the big to smaller sizes. Excluding teeth that exhibit calcification within the pulp chamber, most orifices can typically accommodate a GG-4. The selected and nonrotating GG is placed just within the orifice, and upon activation the head of the handpiece is moved in a circular motion above the GG/orifice pivot point. The belly of the GG serves to flare and blend the orifice into the adjacent axial wall. A preflared orifice produces a smooth, flowing funnel to facilitate the subsequent placement of small-sized hand files. In smaller-diameter canals, which are typically associated with the buccal roots of maxillary molars or the mesial roots of mandibular molars, limit the use of the GG-4 so that its flame-shaped active portion is no more than one bud depth below the orifice.

In noncalcified teeth, GGs are strategically used starting with the larger and sequentially proceeding through the smaller sizes. As such, if the orifice was initially preflared with a GG-4, then proceed to a GG-3. Since the GG-3 is smaller than the GG-4, its loose fit will enable the clinician to use its belly to selectively brush and cut dentin on the outstroke. The goal of this specific procedure is to improve radicular access by intentionally relocating the coronal-most aspect of the canal away from external root concavities and toward the greatest bulk of dentin. Fortuitously, utilizing GGs with a brushing action allows the clinician to more fully address root canal cross-sections that are irregularly shaped anatomically. Following the use of the GG-3, sequentially proceed to the smaller-sized GG-2, then to the GG-1. It is perfectly normal to break the shafts of these smaller-sized GGs when they are correctly and deliberately used like a brush. Breaking the shaft of a GG is clinically not an issue, as the active portion is completely loose in the canal during use.

Preflaring and intentionally relocating the coronal-most aspect of the canal is a strategic decision that will influence all subsequent steps of treatment. As a single example, the coronal aspects of mesial canals of mandibular molars are rarely anatomically centered within a root (Figure 6). Using Ni-Ti rotary files to uniformly expand the coronal portion of a canal outward from its original anatomical position results in preparations that tend to move toward furcal danger. Preparations that are not centered within any given root are predisposed to root thinning, radicular fractures, and strip perforations. [5,13]

Preflaring the coronal one third of a canal is especially important in the clinical situation where the handle of the initially placed file is not aligned with the long axis of a tooth. Clinicians can observe the handle position of the smaller-sized instruments to see if they are upright and parallel to the long axis of the tooth, or if they are skewed off-axis. When the handle of the file is upright, or "on" the long axis of the tooth, then the clinician is able to confirm both coronal and radicular straight-line access. However, when the handle of the initial instrument is "off" the long

axis of the tooth, then recognize that the triangle of dentin must be removed to upright the file handle and position it on axis (Figures 7a and 7b). [7]

Scouter files confirm the presence or absence of straight-line coronal and radicular access. Complete straight-line endodontic access simplifies all subsequent instrumentation procedures and virtually eliminates many cleaning and shaping frustrations.5 Following the use of GGs, the access cavity is almost routinely adjusted and subtly refined with a surgical length tapered diamond to fulfill the mechanical objectives for straight-line access and to promote all ensuing treatment steps. The access preparation should be thought of as a progressive procedure that frequently requires adjustment during canal preparation procedures.

ACCESS REFINEMENT PROCEDURES



Figure 8a. The SINE ultrasonic instruments feature innovative tip configurations, a unique

Figure 8b. An SEM image reveals why the SINE ultrasonic instruments are super efficient

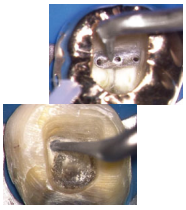

Figure 9a. A SINE instrument with a pointed or rounded tip may be used to track and explo

Figure 9b. A SINE instrument with a football-shaped tip may be used for de-roofing dentin,

[redacted] such as e