In August 1992 in Dentistry Today, I wrote an article, “The SOM: A Quantum Leap for Endodontics.” In the article I made the point that the surgical operating microscope (SOM) was the most significant advancement in dentistry since the advent of the high-speed handpiece and would revolutionize endodontics. My statement raised eyebrows. I now am more convinced about the SOM and the truth of my words than ever before. In 2006, with 14 years of hindsight, the thought was not only valid and vindicated, but perhaps even an understatement. The surgical SOM has indeed revolutionized endodontics and has found wide and growing acceptance amongst general practitioners performing all forms of general dental procedures (Tables 1 to 3).

HISTORICAL BACKGROUND

I met Dr. Gary Carr in San Francisco in 1992 at a dental convention. Two months later I took one of his first SOM classes in San Diego. Dr. Carr brought the SOM into common use in endodontics and was the driving force to give it the foothold in endodontics it deserved, often amidst great skepticism. To tell the story of the SOM without mentioning him would be a significant omission. He is a fine endodontist, inventor, and educator, and his contributions to the profession in a host of endeavors, not limited to the SOM, have been immense. He has trained more than 600 endodontists and their staff in microsurgical and retreatment techniques and is the director and founder of Pacific Endodontic Research Foundation. Dr. Carr is also the creator and developer of TDO, digital office software for endodontists that is widely recognized as the gold standard in endodontic record-keeping. Many of the present advocates of the SOM have been students of Dr. Carr in some fashion, myself included.

In the early 1990s, when Dr. Carr popularized the SOM, rotary nickel-titanium files had not been widely marketed and were not in common use. Warm obturating techniques were not widespread, and bonded obturation was not possible. Ultrasonics were in their infancy. MTA had not been discovered, and there was little emphasis on removal of the smear layer or the vital importance of irrigation or coronal seal. In addition, there were few ideal options for treating endodontic failures. Teeth could not be predictably disassembled (easily have posts and separated files removed), and perforation repair could not be addressed with precision. In endodontics, this changed with the advent of the SOM; procedures were now possible that previously were not.

Table 1. Periodontal Applications of the SOM.

1. Allows surgeon to minimize the size of the surgical site, reducing patient discomfort and healing time.
2. Improves accuracy of microsurgical incisions and suturing with 6-0 through 8-0 sutures, permitti
3. Allows for better inspection and diagnosis of abnormal soft-tissue lesions of the gingiva, palate,
4. Improves visualization of root surface and adjacent intrabony defects for definitive removal of ca
5. Aids identification of microinflammation during re-evaluation following nonsurgical therapy.
6. Helps inspection of the quality of restorations and marginal tissues.
7. Permits micro-level osseous surgery facilitating bone removal without nicking the root surface a
8. Permits accurate subepithelial placement and suturing of membranes and subepithelial connect
9. Improves visualization of implant sites with minimal space between teeth and helps in evaluatin
10. Permits precise control of laser surgery on adjacent teeth without injury to root or implant surfa
11. Permits accurate and easier root amputations and hemisection. Also helps with periapical surg
12. Facilitates sinus lift procedures through direct visualization of the sinus membrane during disse
13. Permits fine dissection of the mandibular and mental nerves for lateral displacement during ma
14. Permits location of the periodontal ligament for atraumatic elevation of roots and root tips durin
15. Improves detection and evaluation of root fractures and abnormalities.
16. Provides upright working conditions, alleviating occupational neck, back, and shoulder problem
17.Provides high-resolution video and 35-mm photography for patient education, enhanced trainin

Tables 1 to 3 used with permission of Global Surgical Corporation.

More importantly, the SOM has demonstrated value in all phases of dentistry. It is not simply an endodontic instrument. Aside from being a very clinically useful instrument, the SOM is a state of mind governed by an overriding philosophy of devotion to excellence. To view the SOM simply in terms of cost and financial reward through increased production is to see only one very small piece of a much larger puzzle. I believe it will create profitability by providing excellent treatment that patients will seek out, rather than simply doing more work per unit of time. A cost-benefit ratio does not take into account the fact that the procedure being performed using the SOM is being done on someone else's mother, father, brother, or sister, ie, someone else's family member. Shouldn't that procedure be undertaken with the very best possible visualization and lighting in order to achieve the finest possible result? Empirically, I would not want a root canal or general dental procedure of any significance performed on me without it. It is the very best single means by which to elevate the quality of the result.

Ironically, dollar for dollar, there is no single tool with more horsepower to raise the standard of care. If one wants to practice at the highest quality level, this is not an optional piece of equipment. The SOM allows clinical dental procedures to be elevated from good to exquisite. If you look for it, but you can't see it, you are unlikely to find it. If you can see it, you can probably do it.

Loupes, while they have function and give the clinician greater visualization, are a poor substitute for the commanding visualization and magnification of the SOM. In every phase of endodontics, and by association general dentistry, there is a significant and dramatic elevation of the possible standard of care available for a clinician to provide the patient through the SOM. In endodontic apical surgery for example, the SOM is invaluable in evaluating where the root end lies within the cortex, the correct amount of bone removal to locate the apex, if an isthmus is present on a root end, if root fractures are present, the source of bleeding in the crypt and drying of the retro-prep, and placement of the apical filling. Similarly, in endodontic retreatment,

observing coronal microleakage under a crown during access is simply not an issue; it is a simple matter to see from what location the leakage arises.

Table 2. Endodontic Applications of the SOM.[3]

1. Allows surgeon to minimize the size of the surgical site, reducing patient discomfort and healing time.
2. Improves accuracy of microsurgical incisions and suturing with 6-0 through 8-0 sutures, permitti
3. Improved lighting and magnification aid in locating additional canals.
4. Aids in retreatment of blocked and obstructed canals.
5. Improves ability to clean prepared canals thoroughly.
6. Accurate depth of retro-prep extension can be more easily assessed.
7.Permits micro-level osseous surgery facilitating bone removal without nicking the root surface an
8. Permits accurate and easier root amputations and hemisection.
9. Improves detection and evaluation of root fractures and abnormalities.
10. Provides upright working conditions, alleviating occupational neck, back, and shoulder problem
11. Provides high-resolution video and 35-mm photography for patient education, enhanced trainir

One additional and intangible factor derived from SOM use is the pure enjoyment the clinician can get from using one as well as the intimate and powerful command given over the procedure. The SOM can take jaded and burned-out clinicians and rejuvenate them. The SOM can make dentistry fun. Watching canal instrumentation literally take shape through subsequent K3 rotary file use (SybronEndo) and assessing the remaining debris after irrigation is empowering. I bond my obturations with RealSeal delivered via the Elements Obturation Unit (both SybronEndo). During obturation, the down-pack of the SystemB (SybronEndo) technique and back-pack with the extruder of the Elements unit after instrumentation is very predictable because all the different steps can be clearly visualized.

Dr. Cliff Ruddle of Santa Barbara, Calif, has often said that, “there is what you know, what you don’t know, and what you don’t know that you don’t know.” As it relates to the SOM, I have heard clinicians say that they are OK with the visualization they possess and that “it works for me.” They don’t know what they don’t know. The vast majority of these individuals have not experienced the tremendous capabilities of the SOM. It is akin to the difference between someone who scuba dives and someone who snorkels. While looking at high-magnification pictures taken through a SOM and appreciating their information and clarity, the experience of actually diving at depth to be inside a shipwreck or amongst coral or schools of fish, turtles, and sharks at 100 feet is something totally different and much more valuable. Being a PADI dive master and having used the SOM for almost 15 years now, I know the analogy is sound.

I have a dental license in the Republic of Palau (Micronesia) and donate my time there.

Because the national hospital does not have a SOM, treating patients at every step in the process of completing a root canal is more challenging for me. The level of visualization and magnification possible with the SOM is simply not comparable to that of loupes or the naked eye; such is the powerful elevation of the standard of care possible with its use. As I travel around the world giving endodontic courses, virtually every dentist I have ever asked who actually uses a SOM says that he or she would never give it up. Clinicians in developing countries hunger for them; such is the value of their appeal and use. Like the clinic in Palau, I wonder how much higher the standard of care could be raised in both the United States and throughout the world if SOMs were the norm. I also wonder how much more physical and psychological stress could be eliminated both for clinicians and patients if SOMs were the global standard.

Table 3. Benefits of the SOM in Restorative Dentistry.

1. Provides refinement in tooth and margin preparation.
2. Allows for closer inspection of restorations and marginal tissues.

3. Improved lighting and magnification aid in caries detection and removal.

4. Improves detection and evaluation of coronal and root fractures and abnormalities.

5. Facilitates cord placement for gingival retraction.

6. Provides for better inspection of impressions.

7. Helps with inspection of marginal fit of restoration (crowns, veneers, inlay/onlay, amalgam, comp

8. Facilitates in finishing and polishing of margins.

9. Assists in gingival contouring or reshaping around teeth and implants.

10. Assists in evaluation after cementation.

The Bar Is Raised

David Clark, DDS

In a 2006 CRA survey, 86% of responding dentists re-ported that they were using magnification. Magnifi

One of the SOM's most important roles will be the dramatic rise in diagnostic sensitivity. For exam

Answers to the most commonly raised questions:

Q: How can you do restorative dentistry on a “wiggly” patient at high magnification when the depth of fie

A: Two answers actually—first, my patients watch a monitor in real time, and when they squirm it r

Doesn't it slow you down?

First, no one should use a SOM clinically until you take a hands-on course. Doctors walk away fro

Many of the techniques you see in dental journals are quite barbaric to teeth and peridontium whe

Dr. David Clark is the founder of the Academy of Microscope En-hanced Dentistry and editor of

Reference

1. Lynch CD, McConnell RJ. The cracked tooth syndrome. *J Can Dent Assoc* 2002;68(8):470-5.

SOM use would lead to greater clinical success. Greater visualization is only a positive benefit

and has no drawbacks; the rewards of its use are all positive, and there are no risks. How many

other instruments or materials in dentistry, or life for that matter, can one say that about? I have

been told from reliable sources that the market saturation of SOM sales in the United States is

less than 5% of the general dental population, while the number is much higher in the

endodontist population (more than 70%). Why is its prevalence so small among the general

dental population?

The answer is apathy, indifference, inertia, a lack of exposure to its benefits, fear of cost, fear of the change that would accompany its introduction, and many similar reasons. In addition, there is a common rationalization that use of the scope will slow down the clinician, and as

such will be a drag on production, and that present methods of visualization are sufficient, and

more enhanced methods are not needed. If clinicians asked themselves honestly, would they

like to be treated with the naked eye, loupes, or the SOM, what would the answer be? Would

they want their wives and husbands treated without it if they had a choice? I strongly suspect

they would prefer the SOM.

At the present time, there are 3 primary SOMs available in the marketplace in North America.

Global Surgical Corporation (globalsurgical.com), Zeiss (zeiss.com), and Seiler Precision

Microscopes (seilerinst.com/micro) offer courses to learn how to use the scope and integrate it

into clinical practice; course information is available on the various Web sites.

While the reader is also directed to the various Web sites for specific information to compare systems and costs, there are several important general details worthy of mention here. First, in the most general terms, clinicians must decide whether they want to document cases with

cameras and/or video recorders. Second, clinicians must decide where they would like the SOM

placed in their operatories, ie, if the SOM needs to be mounted on a wall or on a ceiling. If the

clinician is not going to make video or take pictures, SOM use is simplified. The clinician simply

decides which model or scope is required based on quality, costs, and features, and the SOM

can be introduced very easily into the flow of patient treatment, whether to visualize an entire

procedure or only at selected moments. I perform the entire endodontic process under the SOM

except the injection. I also use the SOM for my overhead light source.

Taking pictures and video to the highest standard during treatment, and editing, archiving, and

using these tools to their greatest benefit in lectures and patient education is a time-consuming

and potentially very expensive process. But for the vast majority of private practice clinicians,

this is not how the SOM would be used, and this complexity is not a factor.

Mounting the SOM in some operatories might be challenging. For the vast majority, though, it

is a matter of consulting with a representative to determine the best mounting configuration

(wall, ceiling, or floor) and then having it installed by a contractor. Retrofitting a SOM into most

operatories is not difficult.

CONCLUSION

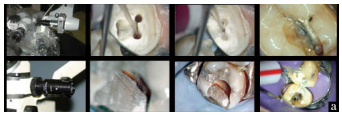

Figures 1a and 1b. The SOM optimizes visualization in many areas of clinical dentistry. Cameras a

Figure 2. High-risk enamel crack at 16 power magnification. Large dentinal crack was pre

Figure 3. Dr. David Clark using a Global G-6 microscope (Global) and real-time video. As

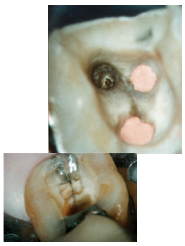

Figure 4. Access and visualization of a broken instrument is afforded by a microscope. Th

Figure 5. The microscope is very useful for visualizing cracked or fractured teeth. This is

In summary, all procedures within endodontics and dentistry can be done more efficiently,

accurately, and to a higher standard with the visualization provided by the SOM. The challenge

to clinicians worldwide is whether they choose to treat their patients with the best possible

means available (the SOM) to create the best clinical results achievable and push the

boundaries of the possible (Figures 1a to 1b and 2 to 5).

Acknowledgement

The author would like to thank Dr. David Clark, Dr. Eric Herbranson, Dr. Gary Carr, Bob

Gannon, and Zeiss, Seiler, and Global SOMs in assembling information for this article.

References

1. Microscope Applications. Periodontal Applications of the Global Microscope. Available at: http://www.globalsurgical.com/dental/dental_benefits_sub.asp?nID=7. Accessed on September 8, 2006.

2. Microscope Applications. Endodontic Applications of the Global Microscope. Available at: ht

tp://www.globalsurgical.com/dental/dental_benefits_sub.asp?nID=8

. Accessed on September 8, 2006.

3. Microscope Applications. Benefits of the Global Microscope in Restorative Dentistry.

Available at:

http://www.globalsurgical.com/dental/dental_benefits_sub.asp?nID=4 . Accessed on

September 8, 2006.

Dr. Mounce lectures globally and is widely published. He is in private practice in endodontics in

Portland, Oregon. Among other appointments he is the endodontic consultant for the Belau

National Hospital Dental Clinic in the Republic of Palau, Koror, Palau (Micronesia). He can be

reached at lineker@aol.com .

Disclosure: Dr. Mounce has no commercial interests in any of the products mentioned in this article.